



Dual Simultaneous Glaucoma Implants

Shawn Cohen, M.D.

Advanced Glaucoma

- **When can we do when trabeculectomy fails or is contraindicated**
 - **CL wearer**
 - **Absence of mobile superior conjunctiva**
 - **Extremely high myopia**

Advanced Glaucoma-Surgical Ideals

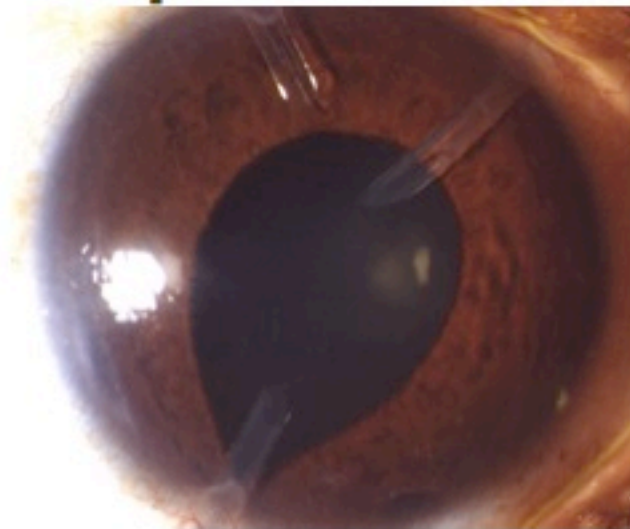
- **Immediate IOP lowering**
- **Achieve low target IOP**
- **Obtain long-term IOP control**
- **Safer than trabeculectomy**
- **Fewer post-operative visits**
- **Simpler regimen than trabeculectomy**
- **Preserve or restore vision**

Surgical Options

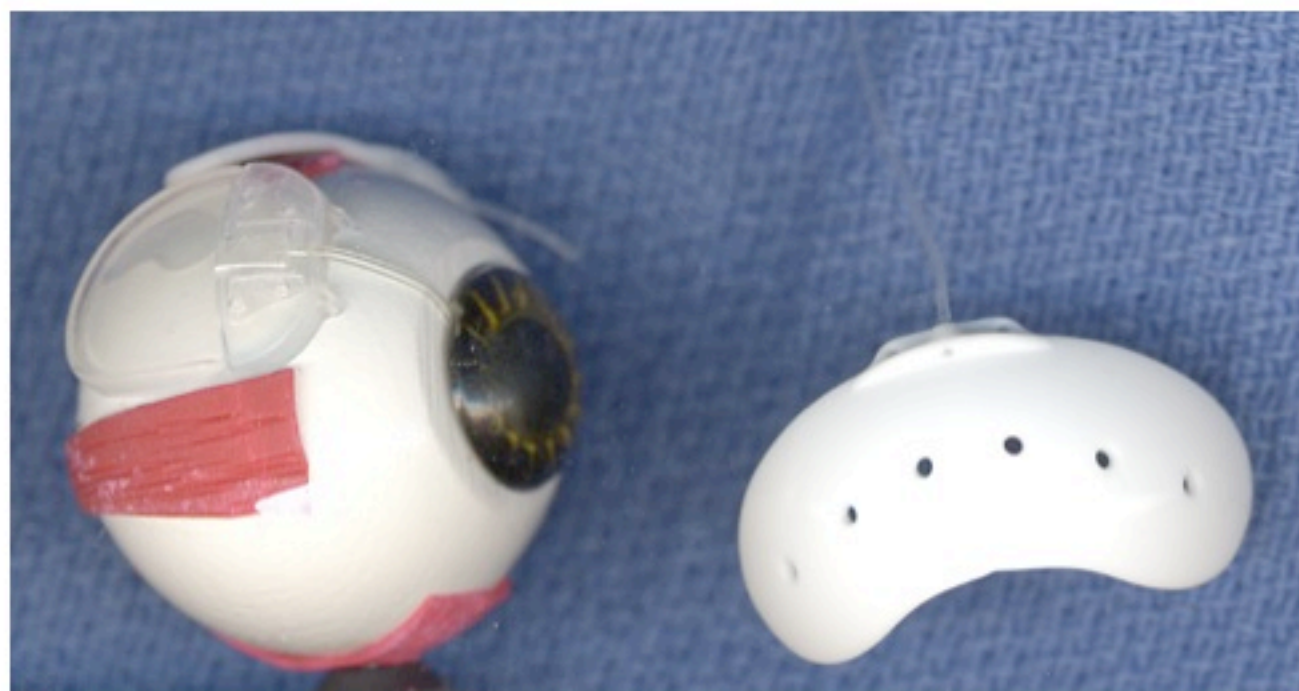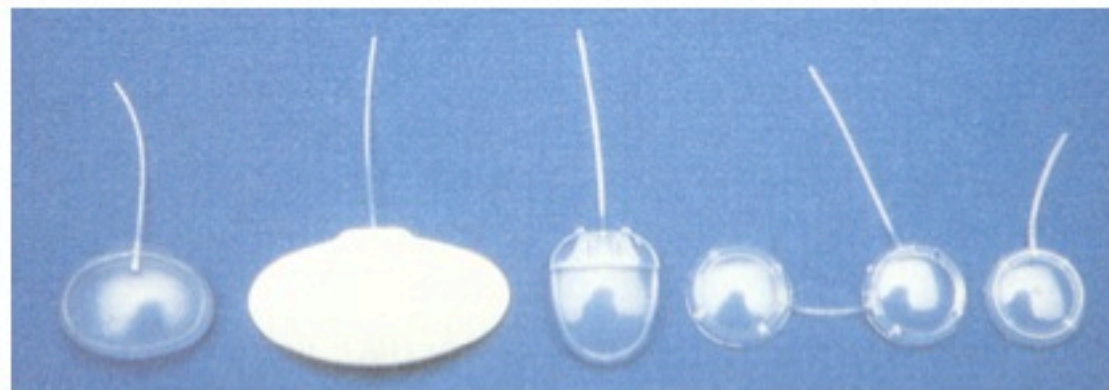
● Options:

- **Holmium laser sclerostomy**
- **Laser cyclodestruction**
- **Single glaucoma implant**
- **Sequential implantation of setons**

- 1) **Immediate**
- 2) **Low**
- 3) **Long-term**
- 4) **Safer**
- 5) **Fewer visits**
- 6) **Simpler regimen**
- 7) **Vision**



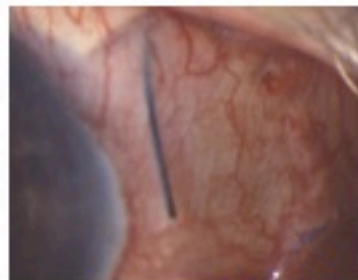
Glaucoma Implants



Ahmed & Baerveldt Implants

● Non-valved (Baerveldt)

- Larger surface area (250 & 350 mm²) thus better long-term IOP control
- No resistance thus ligated to prevent hypotony with a consequent delay:
 - 4-6 weeks without rip-cord
 - 3 weeks with rip-cord
 - Fenestrations unpredictable
- Orphan trab possible for the critical 4-6 week period of delay (ICE syndrome, uveitic gl.)



Ahmed & Baerveldt Implants

- **Valved (Ahmed)**

- Immediate post-operative IOP control
- Limited by 85% rate of hypertensive phase
- Poorer long-term IOP control, partially due to smaller surface area (96 & 184 mm²)

A New Idea From Paul P. Lee

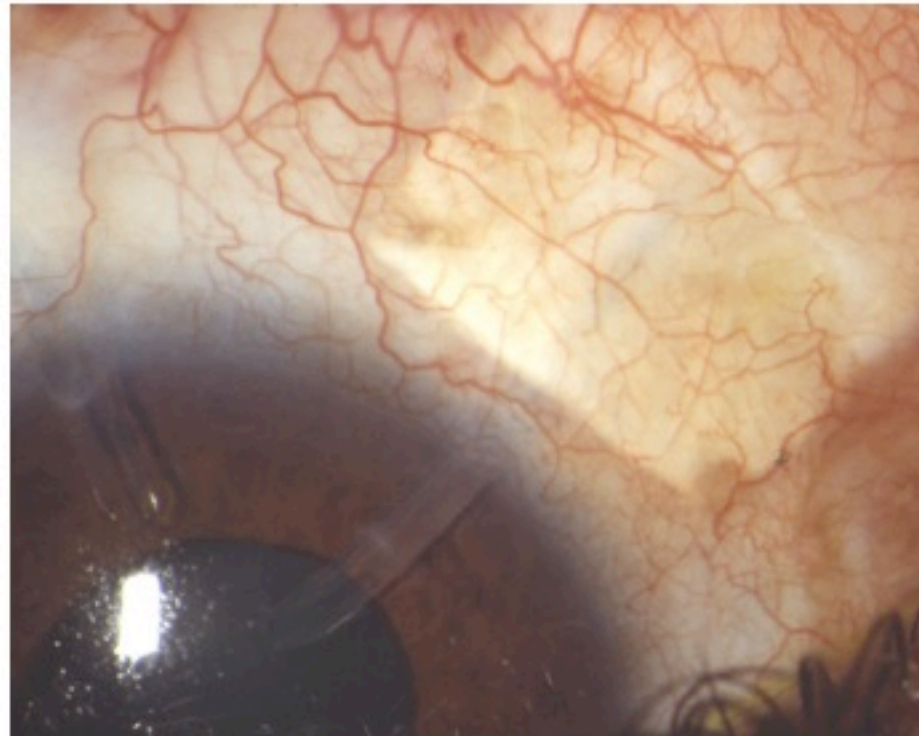
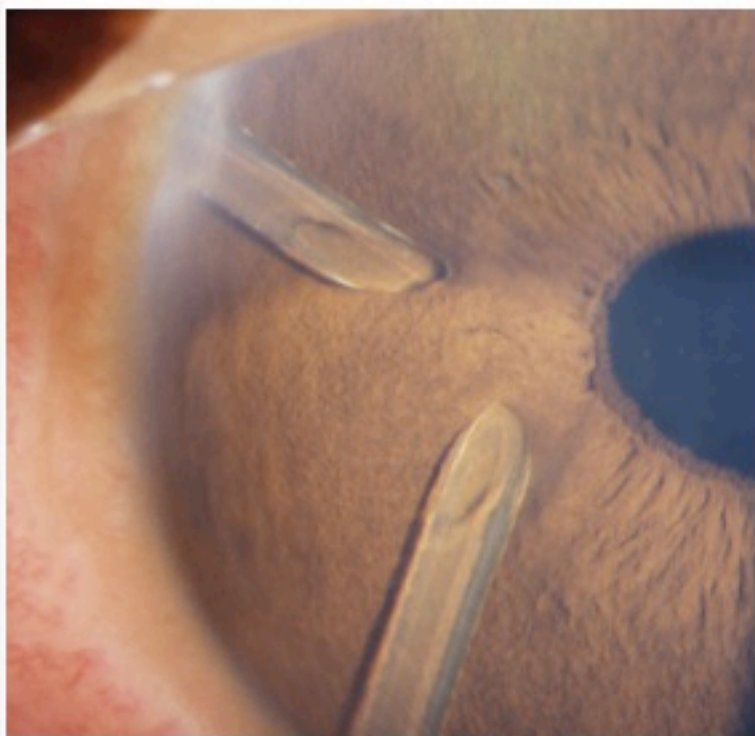


Hypothesis

- **It may be possible to reduce the severity of the hypertensive phase of the valved implant by shunting some aqueous EARLY into a second filtration site.**
- **The simultaneously placed implants function in a complimentary manner:**
 - Immediate IOP reduction; long-term as well
 - Aqueous shunt to reduce htn phase
 - Larger surface area for filtration

Variations in Surgical Technique

- **Superior or temporal approach**
- **Change from 5mm posterior incision to limbal incision 160° with relaxation slits**



Combinations

- **Ahmed S2 (184) + CBI 250 = 434 mm²**
- **Ahmed S3 (96) + CBI 350 = 446 mm²**
- **Ahmed S2 (184) + CBI 350 = 534 mm²**
- **Ahmed + Modified Schocket**
- **Variations:**
 - **Quadrant location**
 - **Rip cord use**
 - **Fenestration use**

Post-op Regimen

- **Current regimen:**
 - **Day 1: Acular & antibiotic qid;**
 - **Cosopt bid by 1 week**
 - **1-2 weeks and at 3-5 weeks (r/c)**
- **F/U 1 month later, q4 months**
- **= 5-6 visits in 6-7 month period**

The Duke Experience

- **?15 cases**
 - Dr. Paul Lee
 - Dr. Leon Herndon
 - Dr. Rand Allingham
 - Dr. Pratap Challa
 - Dr. Shawn Cohen
- **Publication Pending**



The McGill Experience

- **2 cases, a Canadian first!**
- **Thanks to:**
 - **Dr. Miguel Burnier, Chairman**
 - **Dr. Michael Kapusta**



Case 1: NVG

- **74 yo male NVG, DM, hypertension**
- **Vision HM 1-2 feet**
- **IOP 49 on MTMT**
- **Total cup / “beanpot”**
- **Ahmed S3 SN + CBI 350 ST**
- **POD 1: HM 3 feet, IOP 11**
- **POD 6: CF 4 feet, IOP 11**
- **9 months later: CE:20/400**
- **IOP 9 with Cosopt; 12 mm Hg off Cosopt**

Case 2: Extensive 180° scarring

- 88 yo female POHx RD; prosthesis OD
- Vision CF 3 feet, inferiorly only
- IOP 38-50 on MTMT for 2 months
- Total cup / “beanpot”; corneal decomp.
- Ahmed S3 IN + CBI 350 IT
- POD 1: CF 3 feet, IOP 6, small choroidal
- 1 month later: 20/400, IOP 7
- 6 months later: CF 3 feet, IOP 12 No Rx
- Corneal edema limits view

Conclusion

- **“Two tubes, one surgery” - LWH**
- **An alternative to trabeculectomy**

- 1) Immediate IOP lowering
- 2) Achieve low target IOP
- 3) Obtain long-term IOP control
- 4) Safer than trabeculectomy
- 5) Fewer post-operative visits
- 6) Simpler regimen than trabeculectomy
- 7) Preserve or restore vision